

Current thinking about brachycephalic syndrome: more than just airways

Brachycephalic syndrome (BS) describes the result of hereditary abnormalities occurring in dogs and cats from selective breeding for shorter heads and dorsorotation of the face. Although respiratory problems are the best recognised of the problems associated with BS, the problem is not limited to the respiratory tract, writes Kathryn M Pratschke, North East Veterinary Referrals, Northumberland Business Park West, UK

INTRODUCTION

BS results from morphological and functional alterations affecting the upper and lower respiratory tract as well as several other body systems. Although the more common term is brachycephalic obstructive airway syndrome, this is a complex hereditary disease with multiple effects, so it is perhaps more appropriate to move towards a more non-specific term like brachycephalic syndrome as has been recently suggested (Roeder et al, 2013).

Rostral shortening of the skull and maxilla, without concomitant reduction in the associated soft tissues results in a mismatch with excess soft tissues causing increased upper airway resistance (Monnet and Tobias, 2012). These primary anatomic defects lead to secondary changes over time as a result of abnormal airway pressures and airflow dynamics. The primary defects and secondary changes are listed in table 1.

Table 1: This table lists the primary and secondary defects associated with BAOS. The more commonly encountered defects are in bold type, with reported frequency in parentheses.

Primary	Secondary
Stenotic nares (43-96%)	Everted laryngeal sacculles (55-59%)
Elongated soft palate (86-100%)	Laryngeal collapse (8-70%)
Redundant pharyngeal folds	Gastrointestinal signs including vomiting, oesophagitis, gastritis and GORD (37-89%)
Hypoplastic trachea	Bronchial collapse
Nasopharyngeal turbinates	

There are wide reported ranges for the incidence of the more common components of BAOS. This reflects the fact that there are significant differences between the populations reported in different studies (Bright et al, 1997; Riecks et al, 2007; De Lorenzi et al, 2009; Fasanella et al, 2010; Planellas et al, 2012; and Monnet and Tobias, 2012). It is important therefore to remember to compare like with like when interpreting the information reported from such studies.

Stenotic nares and under-sized nasal chambers were among the first described abnormalities associated with BS (Farquharson and Smith, 1942; and Trader, 1949). Everted laryngeal sacculles and laryngeal collapse

were described between 1957 and 1960, and tracheal hypoplasia associated with BS was described in 1972 (Suter et al, 1972; [see Figure 1]).

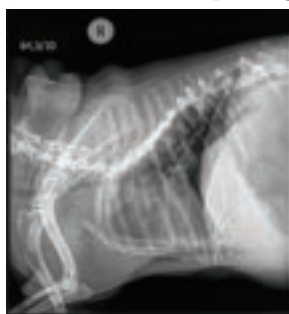


Figure 1: This lateral radiograph demonstrates tracheal hypoplasia as well as the vertebral anomalies (hemivertebrae or cuneiform vertebrae) commonly identified in brachycephalic breeds. Cuneiform vertebrae can lead to distortion of the rib cage.

Nasopharyngeal turbinates have been described in Pugs (Ginn, 2008) and English Bulldogs (Bernaerts et al, 2010), and malformed, aberrantly growing nasal conchae in French and English Bulldogs (Oechtering et al, 2007). Collapse of the left main stem bronchus has been described in Pugs, English Bulldogs and French Bulldogs in 2009 (De Lorenzi et al, 2009) and in English Bulldogs in 2010 (Bernaert et al, 2010).

CLINICAL SIGNS AND PRESENTATION

Dogs with BS can present with a variety of clinical signs ranging in severity from mildly affected to emergency cases in extremis. The most common clinical signs include stertorous breathing, loud snoring, coughing, dyspnoea, gagging, retching, regurgitation, vomiting, exercise intolerance and syncope (Poncet et al, 2005; Fasanella et al, 2010; and Monnet and Tobias, 2012). Sleep difficulties are also described (Hendricks et al, 1987; Hendricks 2004; and Roedler et al, 2013).

Anecdotally, many vets feel that owners do not truly recognise or appreciate the relevance of signs such as snoring, regular waking when asleep (due to apnoeic episodes), noisy breathing and snuffling because they perceive these as being expected if you own a brachycephalic dog. This was confirmed in a survey carried out by Packer and co-workers in 2012, where they found a marked disparity between owners' reports of frequent severe clinical signs but a perceived lack of awareness that this indicated a breathing problem in their dogs. Failure to recognise pertinent clinical signs means that

patients may not present until they become severely affected, or suffer an acute dyspnoeic episode triggered by obesity, stress, heat or exercise (Torrez and Hunt, 2006; Bach et al, 2007; and Fasanella et al, 2010). In some cases patients are presented for gastrointestinal signs including gastro-oesophageal reflux disease (GORD) and vomiting, rather than for a perceived respiratory problem (Poncet et al, 2005; Poncet et al, 2006; Torrez and Hunt, 2006; Monnet and Tobias, 2012) in which case it is important to recognise the link between the conditions (see Figure 2).

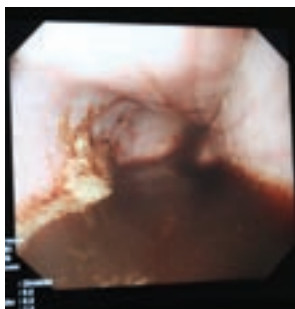

Figure 2: GORD is common in dogs with BS, and can lead to oesophagitis, pharyngitis and laryngitis in addition to causing pain and nausea. The profuse salivation and repeated swallowing motions often seen with reflux disease can be misinterpreted as being related to gastrointestinal disease and nausea.

There has been some recent interest in the possible role of inflammatory mediators in dogs with BS, arising from the use of English Bulldogs as a natural animal model for obstructive sleep apnoea syndrome (OSAS) in humans (Hendricks et al, 1987). As yet, the inflammatory status of dogs with BS is unclear.

BRACHYCEPHALIC SYNDROME IN CATS

Brachycephaly in cats has been described as “a bastardisation of everything that makes cats special” (Malik et al, 2010).

Severe distortion of the nasolacrimal duct has been described (Schlueter et al, 2010) explaining the tendency for severe epiphora in these cats. In addition to stenotic nares, nasal chambers and elongated soft palates, brachycephalic cats are also recognised to have severe dental and ocular issues, as well as a propensity for dermatological conditions caused by inability to groom normally (Malik et al, 2010).

Interestingly, there is a relative lack of published information regarding the respiratory component of BS in cats and most publications concern the dental and ocular problems (La Croix et al, 2001; Blocker et al, 2001; and Schlueter et al, 2009). This may represent a genuine species difference in how brachycephaly manifests, or it may reflect a lower awareness amongst both vets and clients of the potential for diagnosis of BS in cats. The first description of an elongated soft palate causing respiratory obstruction in a cat, was only published in 2012 (Corgozinho, 2012).

DIAGNOSIS OF BRACHYCEPHALIC SYNDROME SIGNALEMENT

The typical signalment will be that of a two to four-year-old brachycephalic patient, although they may be less than a year of age.

CLINICAL HISTORY

The most common clinical signs include stertorous breathing, loud snoring, coughing, dyspnoea, gagging, retching, regurgitation, vomiting, exercise intolerance and syncope.

In a recent survey, a third of brachycephalic dogs were reported to be unable to walk for longer than 10 minutes in the summer and to suffer from heat intolerance (Roedler et al, 2013).

Sleep abnormalities are also recognised in brachycephalic dogs, particularly the English Bulldog. Although the occurrence of such sleep problems has been known since the 1980s (Hendricks et al, 1987), a recent paper puts the situation into stark relief. These authors surveyed the owners of 147 brachycephalic dogs, of whom 31% reported the dog could only sleep with their head elevated; 27% experienced sleep apnoea; 24% attempted to sleep in a sitting position to avoid dyspnoea; 11% had choking fits while asleep; 6% could only sleep by wedging their mouth open; and 6% were almost unable to sleep (Roedler et al, 2013).

PHYSICAL EXAMINATION

Anatomic abnormalities may include stenotic nares, severe shortening of the nasal chambers, body condition score, presence of redundant skin folds, macroglossia and dorsorotation of the skull and epiphora.

Respiratory indicators may include stertor, stridor, dyspnoea, orthopnoea, extension of the head and neck with open mouth breathing, retraction of the commissures of the mouth, external rotation of the elbows and barrelling of the chest, recruitment of abdominal muscles, cyanosis, hyperthermia, and aerophagia.

DIAGNOSTIC TESTS

Haematological and serum biochemistry findings may be normal although polycythaemia may develop in response to chronic hypoxia (Monnet and Tobias, 2012).

Blood gas evaluation – brachycephalic dogs are prone to lower arterial partial pressure of oxygen with higher arterial partial pressure of carbon dioxide (Hoareau et al, 2012).

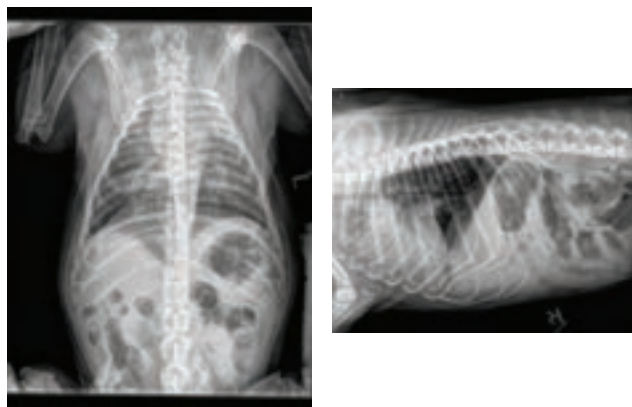
DIAGNOSTIC IMAGING

Thoracic radiographs should be obtained to assess tracheal diameter, thoracic conformation and to check for cardiomegaly, pulmonary oedema or pneumonia (see Figure 3).

Lateral views of the nasopharynx, larynx and cervical trachea may sometimes be helpful in assessing concurrent airway abnormalities and to rule out upper airway masses. Advanced imaging will give a greater degree of detail but is probably not warranted for the majority of clinical cases. Visual assessment of the upper airways is fundamental not only to diagnosis but also assessment of the degree of severity, and is therefore a key part of management. It is essential to not only confirm what abnormalities are present (eg. elongated soft palate, everted laryngeal sacculles, everted tonsils) but also to record these findings

and communicate them clearly to the owner. Many owners have unrealistic expectations for what can be achieved with surgery for brachycephalic animals, so clear and well-informed discussion is important.

Endoscopy of the upper gastrointestinal tract should, in the author's opinion, be part of every brachycephalic evaluation as the incidence of gastro-intestinal problems is high in these patients (Poncet et al, 2005; Poncet et al, 2006; and Planellas et al, 2012).



Figures 3a and 3b: This set of radiographs (dorsoventral and lateral) show changes consistent with aspiration pneumonia with an alveolar pattern in the right cranial and middle lobes as well as the left cranial lobe. There is also moderate gas filling of the gastrointestinal tract and incidental cuneiform vertebrae at T5, 7 and 10. Cuneiform vertebrae can, in some dogs, lead to distortion of the rib cage.

WHAT ROLE CAN MEDICAL MANAGEMENT PLAY?

The main role for medical management is in the initial stabilisation and triage of a respiratory emergency (sedation, cooling, glucocorticoids, supplemental oxygen); to try to alleviate the severity of clinical signs in those with advanced disease (glucocorticoids, diuretics); and for digestive issues such as GORD.

Obese animals should have a weight reduction plan implemented, and exercise restriction is important in patients with more severe disease.

The implications of heat intolerance for the animals environment and exercise should be discussed with the owner, as should elimination of potential airway allergens from the environment eg. cigarette smoke.

1. SURGERY—GENERAL SURGICAL CONSIDERATIONS

PERIOPERATIVE MANAGEMENT

Patients with upper respiratory obstructive conditions are obvious anaesthetic risks, but brachycephalic patients often have an absolute need for one or more surgical procedures in order to alleviate airway obstruction. Cautious anaesthetic management and rigorous monitoring are mandatory to minimise morbidity, particularly prior to induction and intubation and during recovery.

Staff involved in such a case need to be aware that patients may decompensate acutely and emergency tracheostomy may become necessary either pre- or postoperatively. Many sedative and anaesthetic drugs

will relax the muscles which dilate the upper airway while allowing the diaphragm to continue contracting, with the resulting negative pressure causing airway collapse at induction. Both induction and intubation therefore, need to be managed quickly and efficiently. Patients should be kept calm during recovery and only extubated once fully awake. These patients are also prone to reflux/regurgitation while anaesthetised.

The use of nasotracheal oxygen tubes can be beneficial in recovery as these patients do not tolerate nasal prongs, nasal oxygen tubes and face-masks particularly well. Some surgeons advocate withholding food and water for 12-24 hours (Reiter and Holt, 2012) although this practice is not universal and it is not one the author recommends.

PATIENT POSITIONING

Correction of stenotic nares can be achieved with the patient in sternal recumbency with the chin resting on a pad, and the head taped securely to the operating table to prevent movement.

Access to the oropharynx for surgery of the soft palate and/or larynx is tricky and limited. The excessive soft tissue folds typically encountered in brachycephalic breeds further complicate access. Most surgeons' position their patients in open mouth sternal recumbency for surgery of the soft palate, with the maxilla suspended and the mandible secured to the operating table to prevent movement.

A pharyngeal pack should be placed between the soft palate and the larynx during surgery of the soft palate to minimise the risk of aspiration (blood, saliva, refluxate).

2. SURGERY—SELECTED PROCEDURES

STENOTIC NARES/INTRANASAL STENOSIS

The nostril is supported medially by the nasal septum and dorsolaterally by the dorsolateral cartilage. These cartilaginous structures together with the soft tissues covering them form the nares. In normal dogs and cats it is a wide, comma-shaped opening which allows the free passage of air. Stenotic nares have dorsolateral cartilages which lack normal rigidity and tend to collapse medially. This collapse may be either static or dynamic (influenced by airflow pressures). The problem is almost always bilateral, but not necessarily symmetrical.

Surgical correction involves resection of a wedge of tissue from the dorsolateral cartilage, either vertically or horizontally, to widen the nares.

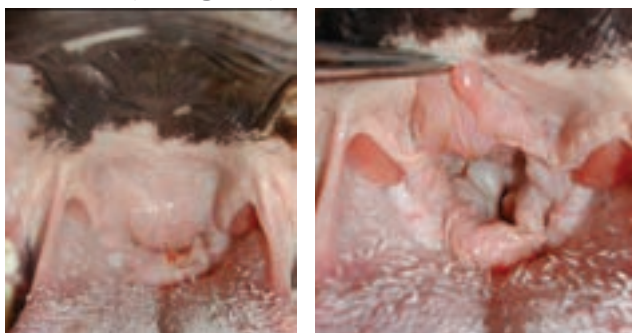
In normal dogs, the nose contributes 80% of the normal resistance during inspiration (Ohnishi and Ogura, 1969). It has been shown that correcting stenotic nares alone where clinical signs are mild and infrequent can improve oxygenation and acid-base balance in brachycephalic dogs (Slawuta et al, 2011).

Oechtering reported laser assisted turbinectomy guided by preoperative cross-sectional imaging and rhinoscopy in 2007 for stenosis that extended intra-nasal. Airway resistance was reduced by approximately 50% after turbinectomy (Oechtering et al, 2007). A subsequent

study from the same group in 2011 however reported that these turbinates regrow! Although only a small percentage of dogs had surgery for re-obstruction, there was no information regarding whether the beneficial effect on airway resistance had been preserved (Schuenemann et al, 2011).

ELONGATED SOFT PALATE/SOFT PALATE HYPERTROPHY

In brachycephalic breeds the soft palate may extend beyond the epiglottis, partially obstructing the airway. It can be sucked between the corniculate processes of the arytenoid during inspiration causing complete obstruction. Some patients will also have excessive folds of palatal and pharyngeal tissues that will contribute to obstruction. Soft palate length is best assessed in anaesthetised patients immediately prior to intubation, with the animal positioned in sternal recumbency. An elongated palate is one that extends beyond the caudal pole of the tonsillar crypts and which overlies the epiglottis by more than a few millimetres (see Figure 4).



Figures 4a and 4b: An elongated palate is one that extends beyond the caudal pole of the tonsillar crypts and which overlies the epiglottis by more than a few millimetres. In these pictures taken from an English Bulldog with a significantly elongated soft palate, Figure 4a shows the soft palate 'sucked into' and plugging the entrance to the airways. Figure 4b, the free end of the soft palate, is being retracted forwards to hold the soft palate free of the larynx, which is now visible.

Several options exist for surgical correction of an elongated soft palate; the precise choice is heavily influenced by the surgeon's preference although patient size may also influence the decision. Resection of the redundant segment of palate can be done with Metzenbaum scissors after creating a 'crush bed' with right-angled forceps; carbon dioxide laser; a bipolar sealing device or harmonic scalpel (Clark and Sinibaldi, 1994, Lorinson et al, 1997, Dunié-Mérigot et al, 2010, Reiter and Holt, 2012).

An alternative procedure, folded flap palatoplasty, was described in 2008, which proposed resection of the bulk of the palatine muscles to thin the palate in addition to shortening it (Findji and Dupré, 2008). Anecdotally, many surgeons like this technique, but there is a lack of objective data regarding the medium-long term outcome including whether it genuinely provides a better outcome.

Regardless of the technique used, complication rates postoperatively are low, other than those related specifically to the severity of the underlying BS (Reiter and Holt, 2012).

LARYNGEAL SACCULE EVERSION AND LARYNGEAL COLLAPSE

Laryngeal collapse is a secondary change resulting from altered airway dynamics and pressure in animals with BS. Three different stages of laryngeal collapse are described in the dog; specific descriptions are not available for cats but in practice the same system is applied. These stages are summarised in table 2.

Grade	Description
Stage I	Eversion of the laryngeal saccules
Stage II	The above plus loss of rigidity of the arytenoid cartilages with medial displacement of the cuneiform processes
Stage III	The above plus collapse of the corniculate processes of the arytenoid cartilage as well as loss of the dorsal arch of the rima glottidis

Table 2: Laryngeal collapse is a progressive condition, divided into three stages of deterioration as described in this table.

The laryngeal saccules themselves are the mucosal lining of the laryngeal ventricles, which are located in front of the vocal folds. High negative inspiratory pressures seen with chronic upper respiratory tract obstruction and dyspnoea lead to prolapse of these pouches of mucosa (Lorinson et al, 1997). This is classed as stage I collapse, and is commonly encountered. Individuals with stage I collapse often show marked improvement after saccule resection plus correction of primary abnormalities such as stenotic nares and elongated soft palate (Lorinson et al, 1997, Torrez and Hunt, 2006, White, 2011). Surgical resection of everted saccules is straightforward in theory, but can be challenging in practice due to limitations on access and visualisation. Resection of too much mucosa can lead to laryngeal webbing from fibrous tissue but inadequate resection leaves obstruction present.

Patients with stage II collapse may have a moderate improvement following correction of stenotic nares, elongated soft palate and saccule resection, combined with weight loss, exercise restriction and medication but improvement for those with stage III collapse is more uncertain. Traditionally, ariepiglottic fold resection (partial laryngectomy), permanent tracheostomy and euthanasia have been considered the only options for management of advanced laryngeal collapse. Laryngeal tie-back has been suggested, similar to the procedure for patients with laryngeal paralysis (Poncet et al, 2006). A modification of the standard tie-back was described in 10 dogs more recently, with long-term follow (median 3.5 years) indicating that all owners considered surgery had been beneficial (White, 2011).

It has been suggested that appropriate control of gastrointestinal disease can help to reduce the progression of respiratory tract disease in those with laryngeal collapse (Poncet et al, 2006); this is also the author's experience.

GASTROINTESTINAL DISEASE, GORD AND BRACHYCEPHALIC ANIMALS

The link between GORD and airway disease is better

characterised in humans than in veterinary patients with a well-recognised phenomenon of GORD-associated airway hypersensitivity (Theodoropoulos et al, 2002; Maher and Darwish, 2010; Harding et al, 2013; and Karbasi et al, 2013). There is increasing evidence supporting a similar scenario in veterinary patients, particularly brachycephalic dogs with obstructive upper airway disease (Poncet et al, 2005; Packer et al, 2012; Planellas et al, 2012; and Roedler et al, 2013). It follows therefore that if the respiratory component is identified and treated, but not the gastrointestinal, the result will be less good than if both are identified and treated.

Treatment will typically include a proton pump inhibitor, a prokinetic and a surface protector. Additional measures such as dietary modification or the use of immune-suppressants are based on individual case assessment and histological findings.

A pilot study recently documented that dogs with BS were significantly more likely to have gastric spirochetes than those without obstructive airway disease (Smith and Pratschke, 2013). Although there is still debate regarding the significance of spirochetes in disease in dogs it is the author's preference to treat with combination antacids and antimicrobials if gastric spirochetes are confirmed in a patient with clinical signs of GORD and gastritis.

CONCLUSIONS

BS is a complex mixture of hereditary defects that progress with time to induce secondary changes some of which are not treatable. Selective breeding for a flat-faced conformation has played a significant role in promoting and perpetuating this disease. Traditionally, BS was considered to involve predominantly the airways, hence the use of terms, such as brachycephalic obstructive airway syndrome. However, these patients can suffer adverse effects on several body systems including digestive, skin and eyes in addition to having sleep disorders, exercise and heat intolerance. For this reason, it may be more appropriate to move towards using a broader term such as BS.

The degree of airway obstruction can be alleviated through surgery, which in some cases will be life saving. These patients are challenging anaesthetic candidates, requiring a careful and efficient approach from all staff involved. It is also important to take account of all morbidities present so that all necessary treatment can be provided and a realistic prognosis discussed with clients.

Better success is achieved by treating patients early, rather than once severe secondary changes have developed. Unfortunately, there is a serious issue with inability on the part of clients, and perhaps also some veterinary surgeons, to recognise the abnormalities and

A leap forward in mobility management



1. Multicentric study in veterinary clinics in Spain, UK, France, Netherlands, in 42 days N=50 dogs. ROYAL CANIN®: 2. Double-blinded, randomized, placebo-controlled, clinical trial, to assess the efficacy of C2P+ cocktail, in osteoarthritis dogs, N=42 dogs, data on file, ROYAL CANIN® 2015. © ROYAL CANIN® SAS 2015. All rights reserved.

ROYAL CANIN

NEW Mobility C2P+™

A synergistic combination of:

- ✓ Curcumin extract
- ✓ Hydrolysed collagen
- ✓ Green tea polyphenols

Visible improvements to mobility, activity and quality of life.^{1,2}



clinical signs of BS as being a genuine problem. All too often, something that is truly abnormal is perceived as normal for the breed. This means that assessment and treatment may not be provided in a sufficiently timely manner, and the prognosis consequently suffers. Although there is growing awareness of the potential welfare issues involved, there is clearly still a requirement for education of veterinary professionals, dog breeders and the wider public.

REFERENCES

- Bach JF, Rozanski EA, Bedenice D et al. Association of expiratory airway dysfunction with marked obesity in healthy adult dogs. *American Journal of Veterinary Research* 2007; 68: 670-5
- Bernaerts F, Talavera J, Leemans J et al. Description of original endoscopic findings and respiratory functional assessment using barometric whole body plethysmography in dogs suffering from brachycephalic airway obstruction syndrome. *The Veterinary Journal* 2010; 183: 95-102
- Blocker T, Van Der Woerd A. A comparison of corneal sensitivity between brachycephalic and Domestic Short-haired cats. *Veterinary Ophthalmology* 2001; 4: 127-30
- Brdecka DJ, Rawlings, CA, Perry AC, Anderson JR. Use of an electrothermal, feedback controlled, bipolar sealing device for resection of the elongated portion of the soft palate in dogs with obstructive upper airway disease. *Journal of the American Veterinary Medical Association* 2008; 233: 1265-1269
- Bright RM, White RAS. Brachycephalic airway obstruction syndrome. A review of 118 cases. *Canine Practice* 1997; 22: 18-21
- Clark GN, Sinibaldi KR. Use of a carbon dioxide laser for treatment of elongated soft palate in dogs. *Journal of the American Veterinary Medical Association* 1994; 204: 1779-1781
- Corgozinho KB, Pereira AN, Cunha SC et al. Recurrent pulmonary edema secondary to elongated soft palate in a cat. *Journal of Feline Medicine and Surgery* 2005; 14: 417-419
- De Lorenzi D, Bertoncell D, Drigo M. Bronchial abnormalities found in a consecutive series of 40 brachycephalic dogs. *Journal of the American Veterinary Medical Association* 2009; 235: 835-840
- Dunié-Mérigot A, Bouvy B, Poncet C. Comparative use of CO₂ laser, diode laser and monopolar electrocautery for resection of the soft palate in dogs with brachycephalic airway obstructive syndrome. *Veterinary Record* 2010; 167: 700-704
- Farquharson J, Smith KW. Resection of the soft palate in the dog. *Journal of the American Veterinary Medical Association* 1942; 100: 427-430
- Fasanella FJ, Shively JM, Wardlaw JL, Givaruangawat S (2010) Brachycephalic airway obstructive syndrome in dogs: 90 cases (1991-2008). *Journal of the American Veterinary Medical Association* 2010; 237:1048-1051
- Findji L, Dupre G. Folded flap palatoplasty for treatment of elongated soft palate in 55 dogs. *Wiener Monatsschrift* 2008; 95: 56-63
- Ginn JA, Kumar MS, McKiernan BC, Powers BE. Nasopharyngeal turbinates in brachycephalic dogs and cats. *Journal of the American Animal Hospital Association* 2008; 44: 243-249
- Harding SM, Allen JE, Blumin JH et al. Respiratory manifestations of gastroesophageal reflux disease. *Annals of the New York Academy of Sciences* 2013; 1300:43-52
- Hendricks JC, Kline LR, Kovalski RJ et al. The English bulldog: a natural model of sleep-disordered breathing. *Journal of Applied Physiology* 1987; 63: 1344-1350
- Hendricks JC. Brachycephalic airway syndrome. In: King L, ed. *Textbook of Respiratory Diseases in Dogs and Cats*. Saunders Elsevier, St Louis 2004: 310-318
- Hoareau GL, Jourdan G, Mellema M, Verwaerde P. Evaluation of arterial blood gases and arterial blood pressures in brachycephalic dogs. *Journal of Veterinary Internal Medicine* 2012; 26: 897-904
- Karbasi A, Ardestani ME, Ghanei M, Harandi AA. The association between reflux esophagitis and airway hyper-reactivity in patients with gastro-esophageal reflux. *Journal of Research in Medical Science* 2013; 18: 473-476
- La Croix NC, van der Woerd A, Olivero DK. Nonhealing corneal ulcers in cats: 29 cases (1991-1999). *Journal of the American Veterinary Medical Association* 2001; 218: 733-735
- Lorinson D, Bright RM, White RAS. Brachycephalic airway obstruction syndrome – a review of 118 cases. *Canine Practice* 1997; 22: 18-21
- Maher MM, Darwish AA. Study of respiratory disorders in endoscopically negative and positive gastroesophageal reflux disease. *Saudi Journal of Gastroenterology* 2010; 16: 84-89
- Malik R, Sparkes A, Bessant C. Brachycephalia – a bastardisation of what makes cats special. *Journal of Feline Medicine and Surgery* 2009; 11: 889-890
- Mills PJ, Dimsdale JE. Sleep apnea: a model for studying cytokines, sleep, and sleep disruption. *Brain, Behaviour and Immunity* 2004; 18: 298-303
- Monnet E, Tobias KM. Larynx. In: Tobias KM, Johnston SA, eds. *Veterinary Surgery Small Animal Volume II*. Elsevier Saunders, Missouri 2012: 1718-1733
- Oechtering TH, Oechtering GU, Nöller C. Structural characteristics of the nose in brachycephalic dog breeds analysed by computed tomography. *Tierärztliche Praxis* 2007; 35: 177-187
- Ohnishi T, Ogura JH. Partitioning of pulmonary resistance in the dog. *Laryngoscope* 1969; 79:1847-78
- Packer RMA, Hendricks A, Burn CC. Do dog owners perceive the clinical signs related to conformational inherited disorders as 'normal' for the breed. A potential constraint to improving canine welfare. *Animal Welfare* 2012; 21 (S1): 81-93
- Planellas M, Cuenca R, Tabar MD et al. Evaluation of C-reactive protein, Haptoglobin and cardiac troponin I levels in brachycephalic dogs with upper airway obstructive syndrome. *BMC Veterinary research* 2012; 8:152
- Poncet CM, Dupre GP, Freiche VG et al. Prevalence of gastrointestinal tract lesions in brachycephalic dogs with upper respiratory syndrome: clinical study in 73 cases. *Journal of Small Animal Practice* 2005; 46:

- 273-279
30. Poncet CM, Dupre GP, Freiche VG, Bouvy BM. Long-term results of upper respiratory syndrome surgery and gastrointestinal tract medical treatment in 51 brachycephalic dogs. *JSAP* 2006; 47: 137-142
31. Reiter Am, Holt DE. Palate. In: Tobias KM, Johnston SA, eds. *Veterinary Surgery Small Animal Volume II*. Elsevier Saunders, Missouri 2012: 1707-1717
32. Riecks TW, Birchard SJ, Stephens JA. Surgical correction of brachycephalic syndrome in dogs: 62 cases. *Journal of the American Veterinary Medical Association* 2007; 230:1324-1328
33. Roedler FS, Pohl S, Oechtering GU. How does severe brachycephaly affect dog's lives. Results of a structured preoperative owner questionnaire. *The Veterinary Journal* 2013; 198: 606-610
34. Schlueter C, Budras KD, Ludewig E et al. Alice Walter and Gerhard U Brachycephalic Feline Noses: CT and Anatomical Study of the Relationship between Head Conformation and the Nasolacrimal Drainage System. *Journal of Feline Medicine and Surgery* 2009; 11: 891-900
35. Schuenemann R, Oechtering GU. Regeneration Potential of Turbinates After Laser Assisted Turbinectomy (LATE). *British Small Animal Veterinary Congress Clinical Research Abstracts*, 2011.
36. Slawuta P, Nicpo J, Doma ska S. Influence of the wing-of-the-nostrils correction procedure on the change of the acid-base balance parameters and oxygen concentration in the arterial blood in French bulldogs. *Polish Journal of Veterinary Science* 2011; 14: 77-80
37. Smith KD, Pratschke KM (2013) Risk factors for gastric spirochete infection in dogs. *Veterinary Surgery* 2013; 42: E58
38. Suter PF, Colgrove DJ, Ewing GO. Congenital hypoplasia of the canine trachea. *Journal of the American Animal Hospital Association* 1972; 8: 120-127
39. Theodoropoulos DS, Pecoraro DL, Efstratiadis SE. The association of gastroesophageal reflux disease with asthma and chronic cough in the adult. *American Journal of Respiratory Infection* 2002; 1:133-46
40. Trader R (1949) Nose operation. *Journal of the American Veterinary Medical Association* 1949; 114: 210-211
41. Torrez CV, Hunt GB. Results of surgical correction of abnormalities associated with brachycephalic airway obstruction syndrome in dogs in Australia. *Journal of Small Animal Practice* 2006; 47: 150-154
42. White RN. Surgical management of laryngeal collapse associated with brachycephalic airway obstruction syndrome in dogs. *Journal of Small Animal Practice* 2012; 53: 44-50

Reader Questions and Answers

1: WHICH OF THE FOLLOWING IS NOT A CLINICAL SIGN TYPICALLY ASSOCIATED WITH BS?

- A. Stertor
- B. Sleep disorder
- C. Coughing
- D. Heat intolerance

2: WHICH OF THE FOLLOWING STATEMENTS IS TRUE WITH REGARD TO BS IN DOGS?

- A. An elongated soft palate is present in only 70% of French bulldogs with BS, and constitutes a palate that extends significantly beyond the caudal border of the palatine tonsillar crypts.
- A. Anatomic changes such as tracheal hypoplasia may be seen in Bulldogs more commonly than other breeds, and must be identified on thoracic x-rays to allow an accurate prognosis.
- A. Laryngeal paralysis with eversion of the saccules is an end-stage finding but may be palliated by means of a cricoarytenoid laryngoplasty (tie-back) with resection of the saccules.
- A. Where stenotic nares are present they are best treated by means of a horizontal wedge resection without sutures, as this technique is least prone to intraoperative complications.

3: WHICH OF THE FOLLOWING IS NOT A CLINICAL SIGN ASSOCIATED WITH BS IN CATS?

- A. Stertor
- B. Vomiting
- C. Epiphora
- D. Dental malocclusion

4: A SURVEY REGARDING OWNERS' PERCEPTION OF HOW SEVERE BRACHYCEPHALY AFFECTS DOG'S LIVES WAS REPORTED IN 2013. ACCORDING TO THE FINDINGS OF THIS SURVEY, WHICH OF THE FOLLOWING STATEMENTS IS TRUE?

- A. 31% of dogs could only sleep with their head elevated
- B. Less than 15% of dogs experienced actual sleep apnoea
- C. A quarter of dogs could not sleep in lateral recumbency
- D. Choking/gagging was not reported in these dogs

5: WHICH OF THE FOLLOWING IS THE DEFINITION OF STAGE II LARYNGEAL COLLAPSE?

- A. Eversion of both laryngeal saccules with cricoid cartilage weakening and softening
- B. Eversion of both laryngeal saccules with cuneiform process weakening and softening
- C. Eversion of both laryngeal saccules with hyoid cartilage weakening and softening
- D. Eversion of both laryngeal saccules with dorsoventral collapse of the laryngeal arch

ANSWERS: 1: C, 2: B, 3: B, 4: A, 5: B